



Macroanatomical Structure of the Lumbosacral Plexus and its Branches in the Indigenous Duck

MT Hussan*¹, MS Islam², and J Alam¹

¹Department of Anatomy and Histology, Faculty of Animal Science and Veterinary Medicine, Patuakhali Science and Technology University, Babugonj, Barisal-8210, Bangladesh

²Department of Anatomy, Histology and Physiology, Faculty of Animal Science and Veterinary Medicine, Sher-e-Bangla Agricultural University, Sher-e-Bangla Nagar, Dhaka-1207, Bangladesh

Abstract

The present study was carried out to determine the morphological structure and the branches of the lumbosacral plexus in the indigenous duck (*Anas platyrhynchos domesticus*). Six mature indigenous ducks were used in this study. After administering an anesthetic to the birds, the body cavities were opened. The nerves of the lumbosacral plexus were dissected separately and photographed. The lumbosacral plexus consisted of lumbar and sacral plexus innervated to the hind limb. The lumbar plexus was formed by the union of three roots of spinal nerves that included last two and first sacral spinal nerve. Among three roots, second (middle) root was the highest in diameter and the last root was least in diameter. We noticed five branches of the lumbar plexus which included obturator, cutaneous femoral, saphenus, cranial coxal, and the femoral nerve. The six roots of spinal nerves, which contributed to form three trunks, formed the sacral plexus of duck. The three trunks united medial to the acetabular foramen and formed a compact, cylindrical bundle, the ischiatic nerve. The principal branches of the sacral plexus were the tibial and fibular nerves that together made up the ischiatic nerve. Other branches were the caudal coxal nerve, the caudal femoral cutaneous nerve and the muscular branches. This study was the first work on the lumbosacral plexus of duck and its results may serve as a basis for further investigation on this subject.

Keywords: Indigenous duck, Pelvic limb, Lumbar plexus, Sacralplexus, Spinal nerves, Birds.

INTRODUCTION

Currently, there is great interest in many different avian species for numerous reasons including, birds serving as companion animals, as models in biological and biomedical research and as sources of high quality protein (McLelland, 1990). Because of this interest in birds on many different levels, there is also increased interest in avian anatomy and physiology. According to the Food and Agriculture Organization (FAO) of the United Nations, over 60 billion chickens and 2 billion ducks are produced worldwide every year, with these figures increasing annually (FAO, 2014). Among poultry in Bangladesh, the duck is the second widespread species following the chicken (Ahmed, 1986). Ducks are well known for their attractive egg's size and their highest resistance against different avian diseases. Duck rearing is one of the possible means breaking out of poverty trap of resource-poor smallholder families in low income countries (Pym *et al.*, 2002).

From more than many decades, intense selections have been performed in both the duck and the broiler chicken to increase the breast muscle. This intensive selection for growth rate in both chickens and ducks has resulted in leg morphology changes, which are likely to influence gait. Ducks has an excellent adaptation capability for locomotion in both land and water media (Duggan *et al.*, 2016). In the livestock, leg weakness is a welfare issue; since it is associated with pain and modified behavior (Caplen *et al.*, 2013). There are very little data available on the prevalence of welfare issues in domestic ducks (Jones und Dawkins, 2010); however, in duck and chicken breeding, selection intensities, achieved growth rates, and carcass weights are similar, and it is likely that locomotion problems also exist to some extent in the domestic duck.

Sets of spinal nerves that serve the same body area are arranged into one large group of nerves. Enlargements called intumescences are found in the spinal cord. These intumes-

*Corresponding author E-mail address: tufazzal84@gmail.com

cences correspond to the formation of the brachial and lumbosacral plexuses that will innervate the thoracic (forelimb) and pelvic limbs (hind limb), respectively. The knowledge of the origin, route, and destination of the plexus components is important to clinical practice and surgery. To understand a little better the features of design that characterize a mammal organism, we must interpret its structure from a comparative perspective, in the analysis of lumbosacral plexuses, even though there are fewer available reports on birds than on mammals. In birds, the mixed nerves that constitute the lumbar, sacral, and pudendal plexuses accomplish the innervation of the pelvic region, hind limb, and tail (Dursun, 2002). Among the nerves present in these regions, the lumbosacral plexus nerves are very important for the diagnosis of Marek's disease. One of the most widespread avian infections, this pathology causes a swelling of peripheral nerves, loss of striated mass, and lethargy. Duck has resistance to Marek's disease and lumbosacral plexus nerves are not affected (Aiello und Mays, 1998). Scientists are curious how these nerves become resistant to Marek's disease. However, there is not any study on the lumbosacral plexus of the duck although there are many studies on the anatomy of the lumbosacral plexus for different types of birds such as the chicken (Serbest *et al.*, 1993), the white turkey (Istanbullugil, 2008), the rock partridge (*Alectoris graeca*) (Can und Ozdemir, 2012a,b), the quail (*Coturnix coturnix japonica*) (Can und Ozdemir, 2011), the pheasant (*Phasianus colchicus mongolicus*) (Istanbullugil *et al.*, 2013), the pigeon (*Columba livia*) (Balkaya und Ozudogru, 2013), the ostrich (*Struthio camelus*) (El-Mahdy *et al.*, 2010), the sparrowhawk (Balkaya und Ozudogru, 2016a,b) and the Eurasian eagle owls (Akbulut *et al.*, 2016). Thus, we have aimed to elucidate the morphological features of the lumbosacral plexus in the indigenous duck and to discuss its similarities and dissimilarities with other avian species.

MATERIALS AND METHODS

A total of six mature indigenous ducks (three of them were male and three were female) were used in this study. The ducks were purchased from the local market near the Faculty of Animal Science and Veterinary Medicine, Patuakhali Science and Technology University, Babugonj, Barisal. All the ducks were apparently healthy and devoid of any external abnormalities. The live body weights of birds varied from 1.5 to 2.0 kg. The ducks were anaesthetized with pentobarbital sodium @50mg/kg body weight i/m. All the ducks were bled to death by giving incision on the right common carotid artery. An incision was made from cloaca to the xiphoid process and expanded around the sternum. The body cavity was opened and internal organs were removed without damage to the nerves forming the lumbosacral plexus. The cadavers were then fixed in 10% formalin solution for 72 hours. The ducks were thoroughly dissected and the nerves of the lumbosacral plexus were photographed separately. The terminology used in this study is compatible with that of the Nomina Anatomica Avium (Baumel *et al.*, 1993).

RESULTS

The network of nerves that innervated the pelvic limb of duck was the lumbosacral plexus, consisted of lumbar and sacral plexus.

Lumbar plexus

In this study, the lumbar plexus was observed on the ventral surface of the preacetabular ilium, in a close association with the cranial division of the kidney. In the duck, the union of three roots of spinal nerves, which included last two lumbar and first sacral spinal nerve (Figure 1A), formed the lumbar plexus. Among three roots of the lumbar plexus, second (middle) root was the highest in diameter and the last root was least in diameter by eye observation. We noticed five branches of the lumbar plexus that innervated mostly the thigh region. The branches of lumbosacral plexus have found different in origin and distribution which include obturator, cutaneous femoral, saphenus, cranial coxal, and the femoral nerve (Figure 1A,1B).The obturator nerve was originated from cranial and middle root of the lumbar plexus. It then travelled caudolaterally parallel to the ventral border of the ilium and left the pelvis through the obturator foramen (Figure 1A). This nerve innervated the obturatorius, ischiofemoralis, and adductor muscle. The cutaneous femoral nerve was originated from the cranial border of the lumbar plexus (Figure 1B). It then moved cranioventrally and innervated the muscle sartorius, iliotibialis cranialis and the skin. Saphenous nerve originated from the caudal root along the caudal border of the lumbar plexus, passed caudolaterally and supplied to the iliopsoas muscle (Figure 1B). The cranial coxal was a small nerve originated from craniodorsal border of the lumbar plexus, turned dorsad innervated the iliotibialis lateralis muscle (Figure 1B).The femoral nerve was the largest and terminal branch of the lumbar plexus. It was divided into three branches immediately after its origin (Figure 1B). The femoral nerve supplied the iliotibialis, femorotibialis, and patellar region of the knee joint.

Sacral plexus

In the present study, we found that the sacral plexus of duck was formed by the six roots of spinal nerves, which contribute to form three trunks (Figure 1C). The first sacral nerve had two branches, cranial and caudal branches. Cranial branch contributed to the formation of brachial plexus (furcal nerve) and caudal branch contributed to the formation of sacral plexus. The caudal branch of first sacral nerve and the ventral branch of second sacral nerve united and formed the cranial trunk. The ventral rami of third and fourth sacral spinal nerves united to form middle trunk. Middle trunk merged with the cranial trunk and generated a new root in the cranial part of the caudal renal division. After the short distance from the origin of the ventral branch of fifth sacral spinal nerve united with the cranial branch of first pudendal nerve and formed the caudal trunk (Figure 1C).The three trunks united medial to the acetabular foramen and formed a

compact, cylindrical bundle, the ischiatic nerve (Figure 1D). Removal of the epineural sheath of the bundle revealed that the plexus breaks up into its branches within the pelvis. The principal branches of the sacral plexus were the (1) tibial and

(2) fibular nerves that together made up the ischiatic nerve. Other branches were: (3) the caudal coxal nerve; (4) the caudal femoral cutaneous nerve; and (5) the muscular branches (Figure 1D).

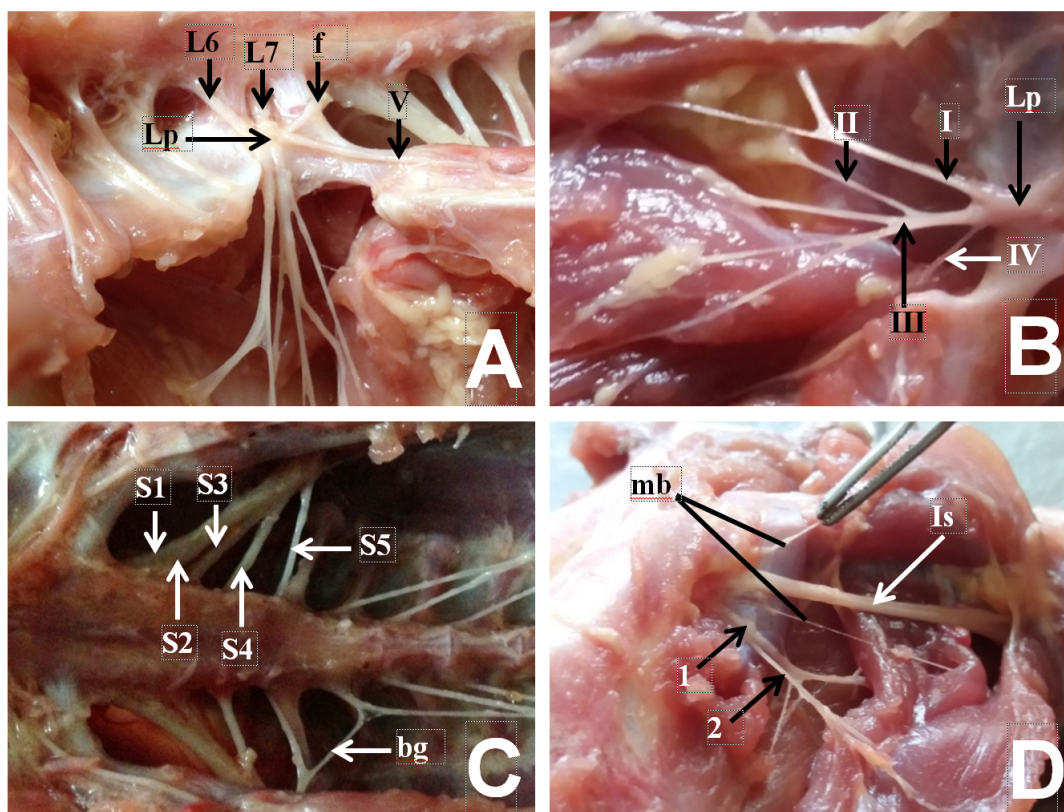


Figure 1: Formation of lumbosacral plexus and its branches in the indigenous duck. A. Lumbar plexus was formed by the union of the ventral branches of last two lumbar and first sacral spinal nerves. B. Branches of lumbar plexus. C. Shows the six roots for the formation of sacral plexus. D. Shows the branches of lumbar plexus. Bg= bigeminus nerve; f= furcal nerve; L6,7= lumbar spinal nerve 6, 7; Lp= lumbar plexus; I= Femoral cutaneous nerve, II= Cranial coxal nerve, III= Femoral nerve, IV= Saphenous nerve, V= Obturator nerve; S1,2,3,4,5= Sacral spinal nerve 1,2,3,4,5; mb= muscular branch; Is= Ischiatic nerve; 1= Caudal coxal nerve, 2= Caudal femoral cutaneous nerve.

DISCUSSION

In this study, it was observed that the lumbar plexus in the duck was formed by the union of three roots of spinal nerves, which included ventral branches of the last two lumbar spinal nerves and first sacral spinal nerve. Different findings were reported in the ostrich (El-Mahdy et al., 2010) and Japanese quail (Bentley und Poole, 2009) where lumbar plexus was formed by the ventral branches of four spinal nerves that include three lumbar and one sacral root. However, similar findings were reported in many avian species where the lumbar plexus was formed by the ventral branches of three spinal nerves such as chicken (Nickel et al., 1977; Dursun, 2002), quail (Fitzgerald, 1969), Japanese quail and rock partridge (Can, 2011; Can und Ozdemir, 2012a). In the present study, the lumbar plexus gave off five large branches

that were distributed mostly in the thigh of duck which included obturator, cutaneous femoral, saphenus, cranial coxal, and the femoral nerve. Similar findings were recorded for the chicken (Nickel et al., 1977; Dursun, 2002), pigeon (Balkaya und Ozudogru, 2013) and for Japanese quail and rock partridge (Can, 2011; Can und Ozdemir, 2012a). In the ostrich, three branches of the lumbar plexus nerves that include the cranial coxal nerve, femoral nerve and obturator nerve were reported (El-Mahdy et al., 2010). In contrast, Can (2011) reported that in rock partridges and Japanese quail, the lumbar plexus had provided six branches, which were ilioinguinal, cutaneous femoral, femoral, cranial coxal, saphenus and obturator nerve. In our study, the obturator nerve was originated from cranial and middle root of the lumbar plexus. It then travelled caudolaterally parallel to the ventral border of the ilium and left the pelvis through the obturator foramen,

which was very similar with that of, reported in domestic fowl (Baumel, 1979; Breazile und Yasuda, 1979; Vanden Berge, 1979). In the ostrich, the nerve extended caudally in the cranial margin of the pubis (El-Mahdy *et al.*, 2010), whereas, Martin *et al.* (1994) reported that this nerve was located medially in the proximal part of the femur.

In our observation in the duck, the cutaneous femoral nerve was originated from the cranial border of the lumbar plexus. It then moved cranioventrally and innervated the muscle sartorius, iliotibialiscranialis and the skin. The same findings were reported for flamingo (Berge, 1976), domestic fowl (Nickel *et al.*, 1977; Dursun, 2002) and ostrich (El-Mahdy *et al.*, 2010). In addition, Can (2011) stated that this nerve innervated the skin around the lateral thigh. In the present study, the saphenous nerve originated from the caudal root along the caudal border of the lumbar plexus, passed caudolaterally and supplied to the iliacus muscle of duck, which was in the same line with that of findings as in domestic birds reported by Dursun (2002) and Nickel *et al.* (1977). By contrast, El-Mahdy *et al.* (2010) reported that the saphenous nerve originated from the femoral nerve in ostrich. In the duck, the cranial coxal was a small nerve originated from craniodorsal border of the lumbar plexus, turned dorsad innervated the iliotibialislateralis muscle which is similar to that of quail (Fitzgerald, 1969) and ostrich (El-Mahdy *et al.*, 2010). In our findings in the duck, the femoral nerve was the largest and terminal branch of the lumbar plexus, which is similar as in domestic fowl (Nickel *et al.*, 1977; Dursun, 2002) and ostriches (El-Mahdy *et al.*, 2010). In duck, the femoral nerve was divided into three branches immediately after its origin. Fitzgerald (1969) and Can (2011) reported that the femoral nerve divided into three branches between the body and thigh in quail and Japanese quail. The ramification of the femoral nerve in the duck was similar to that reported for quail (Fitzgerald, 1969) and Japanese quail (Can, 2011). Contrary to these reports, Can (2011) and Can und Ozdemir (2012a) stated that the nerve divided into five branches in the rock partridge.

El-Mahdy *et al.* (2010) stated that this nerve gave rise to six branches in the ostrich and that was divided into two branches in the pigeon following its origin (Balkaya und Ozudogru, 2013).

It was detected that the sacral plexus of the duck was formed by ventral branches of synsacral nerves leaving from the canal of synsacrum and this plexus was linked to the lumbar plexus via the furcal nerve and to the pudendal plexus with the bigeminus nerve. In our study, the sacral plexus of duck was formed by the ventral rami of six synsacral spinal nerves, which contributes to form three trunks. It was reported that, the sacral plexus was formed by four ventral rami of synsacral nerves for the quail (Can und Ozdemir, 2011), the pigeon (Balkaya und Ozudogru, 2013), the pheasant (Istanbullugil *et al.*, 2013), the chicken (Serbest *et al.*, 1993) and five for the rock partridge (Can und Ozdemir, 2012b), six for the white turkey (Istanbullugil, 2008) and seven for the ostrich (El-Mahdy *et al.*, 2010). In the duck, the caudal branch of first sacral nerve and the ventral branch of second sacral nerve were united and formed the cranial trunk. The ven-

tral rami of third and fourth sacral spinal nerves were united to form middle trunk. Middle trunk merged with the cranial trunk and generated a new root in the cranial part of the caudal renal fossa. After the short distance from the origin of the ventral branch of fifth sacral spinal nerve united with the cranial branch of first caudal spinal nerve and formed the caudal trunk. Similar finding was reported that ventral branches of synsacral nerves, forming the sacral plexus, formed three trunks: the cranial trunk, the middle trunk and the caudal trunk (Istanbullugil, 2008; Can und Ozdemir, 2012b; Balkaya und Ozudogru, 2013); however, there were two trunks in the case of the ostrich, namely the cranial trunk and the caudal trunk (El-Mahdy *et al.*, 2010). It was stated that three for the white turkey (Istanbullugil, 2008), five for the ostrich (El-Mahdy *et al.*, 2010), two for the rock partridge (Can und Ozdemir, 2012b), the pheasant (Istanbullugil *et al.*, 2013), the quail (Can und Ozdemir, 2011), the pigeon (Balkaya und Ozudogru, 2013) and the chicken (Serbest *et al.*, 1993) ventral branches of synsacral nerves participated in the formation of the cranial trunk. It was also reported that the last two ventral branches of synsacral nerves participated in the formation of the caudal trunk (El-Mahdy *et al.*, 2010; Can und Ozdemir, 2012b); however, one ventral branch of synsacral nerve participated in the formation of the caudal trunk regarding the pheasant (Istanbullugil *et al.*, 2013). It was also mentioned that the middle trunk was formed by only one ventral branch of synsacral nerve (Can und Ozdemir, 2011; Balkaya und Ozudogru, 2013).

The ischiatic was reported as the thickest nerve leaving from the sacral plexus in poultry, and it was originated from the first four roots of the sacral plexus (Nickel *et al.*, 1977; Martin *et al.*, 1994; Dursun, 2002; El-Mahdy *et al.*, 2010). It was stated that the nerve ischiadicus was formed by the union of the cranial trunk, the middle trunk and the caudal trunk in the pheasant (Istanbullugil *et al.*, 2013), the white turkey (Istanbullugil, 2008), the chicken (Serbest *et al.*, 1993), the pigeon (Balkaya und Ozudogru, 2013), the rock partridge (Can und Ozdemir, 2012b) and the quail (Can und Ozdemir, 2011). It was determined firstly in our study that the cranial trunk and the middle were unified, which then united the caudal trunk with these roots. The three trunks united medial to the acetabular foramen and formed a compact, cylindrical bundle, the ischiatic nerve. Removal of the epineural sheath of the bundle revealed that the plexus breaks up into its branches within the pelvis. The principal branches of the sacral plexus were the (1) tibial and (2) fibular nerves that together made up the ischiatic nerve. Other branches were: (3) the caudal coxal nerve; (4) the caudal femoral cutaneous nerve; (5) the muscular branches. It was stated that four branches originated in the quail (Can und Ozdemir, 2011) and the rock partridge (Can und Ozdemir, 2012b), respectively, from the sacral plexus cranially to caudally, namely the mutual root of fibular nerve and tibial nerve, the coxal caudal nerve, the cutaneous femoral caudal nerve and the rami musculares, but in the pigeon (Balkaya und Ozudogru, 2013) firstly the coxal caudal nerve, the mutual root of fibular nerve and tibial nerve, the cutaneous femoral caudal nerve and the rami musculares. It was also reported that five branches originated in the white

turkey (Istanbullugil, 2008), the pheasant (Istanbullugil et al., 2013) namely the mutual root of fibular nerve and tibial nerve, the coxal caudal nerve, the rami musculares, the cutaneous femoral caudal nerve and finally the second part of the rami musculares.

We explored the morphological structure of the lumbosacral plexus and its branches in the indigenous duck in this study. In conclusion, it can be stated that the origin and branching of lumbosacral plexus of indigenous duck was conformed to that in other avian species; however, we found some differences in the nerves forming the lumbosacral plexus and in their branching. These differences may be species related or variation in the peripheral nervous system. This study was the first work on the lumbosacral plexus of indigenous duck and results may serve as a basis for further investigation on this topic.

References

- Ahmed S, 1986. Duck production in Bangladesh. Duck production science and world practice. University of New England, Armidale, Australia.
- Aiello SE, Mays A, 1998. The Merck Veterinary Manual. 8. Auflage. Merck & CO. INC. Whitehouse Station NJ, USA.
- Akbulut Y, Demiraslan Y, Aslan K, Koban A, 2016. The macroanatomy of the sacral plexus and its nerves in eurasian eagle owls (*Bubo bubo*). *Anatomia Histologia Embryologia* 45: 367–372.
- Balkaya H, Ozudogru Z, 2013. Macroanatomic and subgross study on the plexus lumbosacralis and its branches of pigeon (*Columba livia*). *Ataturk University Journal of Veterinary Sciences* 8: 21–33.
- Balkaya H, Ozudogru Z, 2016a. Macroanatomical aspects of the lumbar plexus and its branches in the sparrowhawk. *Anatomia Histologia Embryologia* 45: 67–72.
- Balkaya H, Ozudogru Z, 2016b. Macroanatomical aspects of the sacral plexus and its branches in sparrowhawk. *Journal of Applied Animal Research* 44: 77–82.
- Baumel JJ, 1979. Osteologia. In: *Nomina Anatomica Avium* (Baumel JJ, King AS, Lucas AM, Breazile JE and Evans HE, eds). London: Academic Press.
- Baumel JJ, King SA, Breazile JE, Evans HE, Vanden Berge JC, 1993. Handbook of Avian Anatomy. *Nomina Anatomica Avium*. 2. Auflage. Cambridge, MA: Published by the Club.
- Bentley MT, Poole TJ, 2009. Neurovascular anatomy of the embryonic quail hindlimb. *The Anatomical Record* 292: 1559–1568.
- Berge JCV, 1976. M. iliotibialis medialis and a review of the m. iliotibialis complex in flamingos. *The Auk: Ornithological Advances* 93: 429–433.
- Breazile JE, Yasuda M, 1979. Systema nervosum peripheriale. In: *Nomina Anatomica Avium* (Baumel JJ, King AS, Lucas AM, Breazile JE and Evans HE, eds). London: Academic Press.
- Can M, 2011. Bildircin (*Coturnix coturnix japonica*) ve Kaya kekligi'nin (*Alectoris graeca*) Plexus lumbosacralis'i Uzerinde Karsilastirmali, Makroskobik ve Subgross Calismalar. Erzurum: Saglik Bilimleri Enstitüsü, Anatomi (Veteriner) Anabilim Dalı, Doktora Tezi, Ataturk Universitesi.
- Can M, Ozdemir D, 2011. Macro-anatomic investigations on the plexus lumbosacrales of japanese quail (*Coturnix coturnix japonica*). *Ataturk University Journal of Veterinary Sciences* 6: 31–45.
- Can M, Ozdemir D, 2012a. Macro-anatomic investigations on the plexus lumbales of rock partridge (*Alectoris graeca*). *Ataturk University Journal of Veterinary Sciences* 7: 123–129.
- Can M, Ozdemir D, 2012b. Macro-anatomic investigations on the plexus sacralis of rock partridge (*Alectoris graeca*). *Journal of the Faculty of Veterinary Medicine, Kafkas University* 18: 141–146.
- Caplen G, Colborne GR, Hothersall B, Nicol CJ, Waterman-Pearson AE, Weeks CA, 2013. Lameness in broiler chickens respond to non-steroidal anti-inflammatory drugs with objective changes in gait function: a controlled clinical trial. *The Veterinary Journal* 196: 477–82.
- Duggan BM, Hocking PM, Clements DN, 2016. Gait in ducks (*Anas platyrhynchos*) and chickens (*Gallus gallus*) - similarities in adaptation to high growth rate. *Biology Open* 0: 1–9. doi:10.1242/bio.018614.
- Dursun N, 2002. The Anatomy of Domestic Birds. Ankara: Medisan.
- El-Mahdy T, El-Nahla SM, Abbott LC, Hassan SA, 2010. Innervation of the pelvic limb of the adult ostrich (*Struthio camelus*). *Anatomia Histologia Embryologia* 39: 411–425.
- FAO, 2014. FAOSTAT (database on the internet). <http://faostat.fao.org/default.aspx>. Accessed 20 May 2015.
- Fitzgerald TC, 1969. The Coturnix Quail, Anatomy and Histology. Ames, IA: The Iowa State University Press.
- Istanbullugil FR, 2008. Beyaz hindide plexus sacralis olusumu ve plexus sacralis' ten cikan sinirlerin makroanatomik ve subgross incelenmesi. Dissertation, MSc Thesis. Yüzüncü Yil University, Institute of Health Sciences, Department of Anatomy, Van.
- Istanbullugil FR, Kardag H, Sefergil S, Ince Gezer N, Alpak H, 2013. Formation of the plexus sacralis in pheasants (*Phasianus colchicus mongolicus*) and macroanatomic investigation of the nerves originating from the plexus sacralis. *Turkish Journal of Veterinary and Animal Sciences* 37: 160–163.

- Jones TA, Dawkins MS, 2010. Environment and management factors affecting pekin duck production and welfare on commercial farms in the uk. *British Poultry Science* 51: 12–21.
- Martin HD, Kabler R, Sealing L, 1994. The avian coxofemoral joint: a review of regional anatomy and report of an open-reduction technique for repair of a coxofemoral luxation. *Journal of the Association of Avian Veterinarians* 8: 164–172.
- McLelland J, 1990. *A Colored Atlas of Avian Anatomy*. London, England: Wolfe publishing LTD.
- Nickel R, Schummer A, Seifirle E, 1977. *Anatomy of the Domestic Birds*. Berlin, Hamburg: Verlag Paul Parey.
- Pym RAE, Lanada EB, Morbos EY, 2002. Case studies of family poultry development. May 13-July 5.
- Serbest A, Bahadır A, Bahri Y, Yılmaz O, 1993. Tavuklarda plexus sacralis ile bunu oluşturan ramus ventralis' lerin makro-anatomik ve subgros incelenmesi. *Uludağ University Journal of the Faculty of Veterinary Medicine* 2: 46–54.
- Vanden Berge JC, 1979. Myologia. In: *Nomina Anatomica Avium* (J. J. Baumel, A. S. King, Lucas. AM, J. E. Breazile and H. E. Evans, eds). London: Academic Press.